

SMILES in the SPOTLIGHT

**LEADERS IN NORTH TEXAS DENTISTRY
CREATING UNFORGETTABLE SMILES**

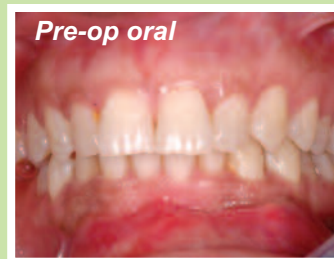Microvascular Reconstruction

Defects of the face, neck and mouth are often created when removing tumors or as the result of severe facial injury. Proper reconstruction is vital to allow patients to maintain the highest quality of life and self-esteem. Dr. Fayette Williams is the only Oral & Maxillofacial Surgeon in the DFW area performing microvascular reconstructive surgery, and one of less than 30 Oral & Maxillofacial Surgeons in the nation trained in this state-of-the-art form of reconstruction. After finishing his six-year surgical residency, Dr. Williams completed an additional two years of fellowship training at the University of Michigan to learn this specialized surgery.

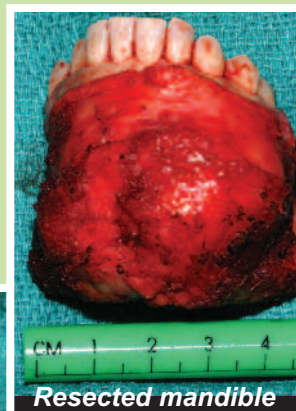
Microvascular reconstructive surgery is one of the most advanced options in restoring facial form and function following the removal of large facial and oral tumors. Tissues from the patient's own body are transplanted into the orofacial defects to restore function and appearance. These transplants (known as "flaps") can be in the form of skin, muscle, bone, or any combination. The flap is removed from the body along with blood vessels that supply nourishment to the flap. The blood vessels are reconnected to vessels around the facial defect under a microscope using sutures smaller than a human hair. Once blood flow is re-established, the transplanted tissue remains alive just as it did in its original location. Because the flap is completely freed from another part of the body, this technique is often referred to as "free flap surgery" or "free tissue transfer."

When necessary for microvascular jaw reconstruction, Dr. Williams utilizes computer-guided virtual surgery to plan the reconstruction with increased precision and potentially reduced operating time. Using this advanced technology, Dr. Williams works closely with biomedical engineers from Medical Modeling on each case to offer truly customized surgical solutions for each patient.

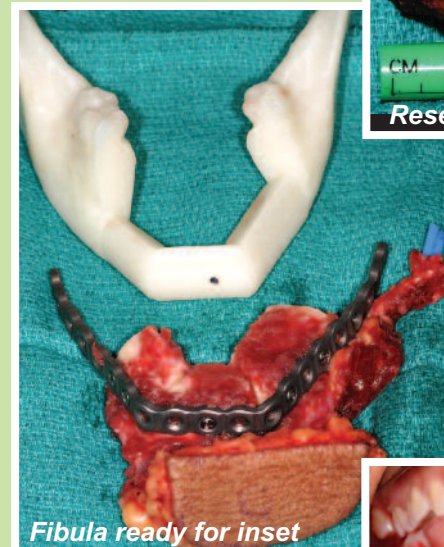While not all patients are candidates to undergo this form of reconstruction, Dr. Williams also performs many other forms of facial reconstructive surgery. The optimal reconstructive technique is tailored to each patient and chosen based on the patient's wishes, goals, and available options.



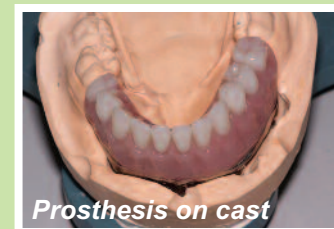
Pre-op oral



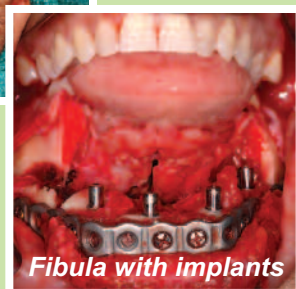
Resected mandible



Fibula ready for inset



Prosthesis on cast



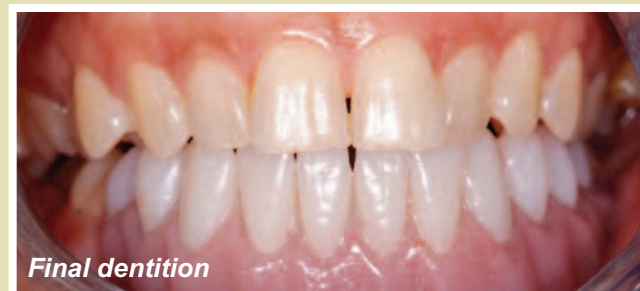Fibula with implants

CASE PRESENTATION

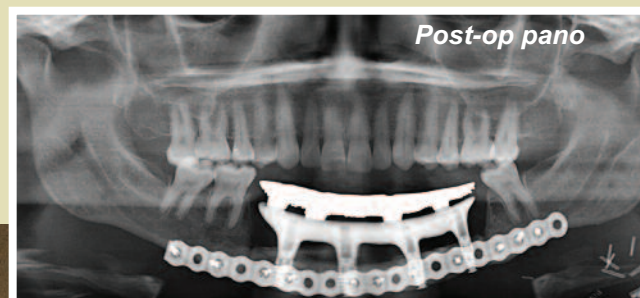
This 44-year-old healthy female presented with a slowly enlarging mass in her chin. A panorex revealed a multilocular radiolucency extending across the mandible from #19 to #28. An incisional biopsy under local anesthesia revealed ameloblastoma. Her dentition was in good repair and cosmetically excellent.

TREATMENT PLAN

Resection of this tumor required at least 1cm of normal bone in every direction, which was expected to result in a mandibular continuity defect spanning from #18 to #30. The patient was a public speaker and was devastated to learn she would lose most of her lower teeth. With conventional non-vascularized bone grafting, this would require resection of the mandible during the first surgery, bone grafting from the iliac crest during a second surgery three months later, placement of dental implants and soft tissue procedures 4-6 months later, followed by another 4-6 months for osseointegration. This normally requires 15-18 months of multiple operations before the patient's dentition is restored. We performed an operation to resect the tumor, immediately reconstruct the defect with a fibula free tissue transfer, and immediate placement of dental implants into the vascularized bone all in one operation. A preoperative cone beam CT scan was used to fabricate models to virtually plan the resection and reconstruction.



Final dentition



Post-op pano

PROCEDURE

The patient was taken to the operating room under the care of Drs. Kao and Williams. Her tumor was excised through the mouth, thus avoiding a large neck incision. The nerve canal on the right was unroofed to preserve the mental nerve, while the left mental nerve was sacrificed where it entered the tumor. Occlusion was maintained with a temporary external fixation device to hold the remaining posterior mandibular segments in their original relationship throughout the surgery. The left fibula was harvested along with the peroneal artery and vein which supply the bone. A 12cm segment of the fibula was shaped via wedge osteotomies to conform to the prefabricated custom mandibular reconstruction plate used to fixate the bone flap. This pre-bent plate with the fibula construct was placed into the mouth and fixated to the remaining mandible to re-establish bony continuity. A small 3cm incision was placed in the left neck to access the facial artery and vein. These vessels were anastomosed to the peroneal artery and vein supplying the fibula under a microscope with 9-0 nylon sutures. Once the bone flap was found to be viable and bleeding, four dental implants were placed and the incisions were closed primarily. The patient healed uneventfully from her surgery and underwent a minor soft tissue revision (vestibuloplasty) three months later to prepare for the restorative phase of treatment.

RESULTS

A satisfactory smile was obtained only 4 months later, consistent with current osseointegration healing periods. A hybrid prosthesis was fabricated with laboratory support from Darrel Clark, CDT in Weatherford, TX. The prosthesis consisted of a milled bar fit to the dental implants. Additional abutments were laser-welded to the bar in an ideal position to support the dentition. She reports no difficulty with ambulation and is able to eat a full diet with her fixed hybrid prosthesis. As can be seen in the postoperative panorex, the obvious drawback of the fibula is the minimal height of bone compared to the dentate mandible. However, with modern implant and surgical technology these patients can have their dentition restored in one-fourth of the time span required by traditional reconstructive techniques.

Fayette Williams, DDS, MD



Fayette Williams, DDS, MD is Clinical Faculty at John Peter Smith Hospital in Fort Worth, TX and Adjunct Assistant Professor at The University of Texas Southwestern Medical Center in Dallas. In 2010, he completed a fellowship in Maxillofacial Oncology and Reconstructive Surgery at the University of Michigan in Ann Arbor.

After returning from his fellowship, Dr. Williams joined the faculty at John Peter Smith Hospital in Fort Worth and the private practice of Facial & Oral Surgery Associates. Dr. Williams is the only oral & maxillofacial surgeon in the DFW area performing state-of-the-art microvascular reconstruction of the head and neck. He has lectured on a national level and has authored three textbook chapters on oral cancer and reconstructive surgery. At John Peter Smith Hospital, he is Vice-Chairman of the Cancer Committee. Dr. Williams' passion lies in the treatment and reconstruction of oral cancer and their related defects.

Herman Kao, DDS, MD



Dr. Kao is a dedicated private and academic surgeon, which enables him to enjoy the full spectrum of dentoalveolar, dental implant, orthognathic surgery, trauma/reconstructive surgery, and cleft lip and palate surgery. With state of art technology, his practice utilizes computer virtual planning for dental-implant and corrective jaw surgeries. Dr. Kao is also passionate about serving the underserved. He is a recipient of the Sally Hopper Golden Crown Award for his Pro Bono services to local dental health clinics.

Academically, Dr. Kao is Clinical Faculty at John Peter Smith Hospital where he performs and teaches major facial trauma and reconstructive surgery. He is actively involved in the education and training of the interns and Oral/Maxillofacial Surgery residents. Because of his dedication to patient care and satisfaction, he sits on the Patient Care Committee and the Physician Advisory Committee. In addition, Dr. Kao holds an appointment of Adjunct Assistant Professor at UT Southwestern Medical Center, where he gives regular Grand Round lectures to the faculty and residents.

**For more information concerning this case,
contact Dr. Williams at www.facialoralsurg.com
or call 817.927.1325.**